

Occult systemic malignancy masquerading as thrombotic thrombocytopenic purpura–hemolytic uremic syndrome

Kristin K. Francis, MD, Kiarash Kojouri, MD, MPH, and James N. George, MD

Hematology–Oncology Section, Department of Medicine, The University of Oklahoma Health Sciences Center, Oklahoma City, OK

The occurrence of microangiopathic hemolytic anemia and thrombocytopenia in patients with disseminated malignant disorders has been well documented. However, when systemic malignancy is not clinically apparent, these features may be misdiagnosed as thrombotic thrombocytopenic purpura–hemolytic uremic syndrome (TTP-HUS), and patients may be treated with plasma exchange, a procedure with substantial risk. Among the 329 patients in the Oklahoma TTP-HUS Registry, 1989–2005, 12 patients who were treated with plasma exchange for presumed TTP-HUS were later found to have a systemic malignancy. Details about one such patient, a 52-year-old woman who had a history of breast cancer, are presented. Although some of her clinical features were atypical for TTP-HUS, and the possibility of recurrent breast cancer was carefully considered, no evidence of cancer was found and plasma exchange treatment for TTP-HUS was initiated. Disseminated breast cancer was not revealed until a microscopic examination of tissue sections was made at autopsy. In retrospect, a bone marrow biopsy might have documented the presence of metastatic cancer in this patient. Hematologists/ oncologists must be aware that patients with clinically diagnosed TTP-HUS may have an occult systemic malignant disorder.

Evaluation of patients with unexpected thrombocytopenia and anemia is often difficult, and management decisions are often uncertain. When the thrombocytopenia is severe and the anemia has features of microangiopathic hemolysis (eg, fragmented red blood cells [RBCs], increased levels of lactate dehydrogenase [LDH] and indirect bilirubin, and a negative direct Coombs' test), the diagnosis of thrombotic thrombocytopenic purpura–hemolytic uremic syndrome (TTP-HUS) must be considered.

Although the presence of neurologic abnormalities and renal failure supports the diagnosis of TTP-HUS, many patients have only thrombocytopenia and microangiopathic hemolytic anemia.¹ There are no clinical features or laboratory tests that can confirm the diagnosis of TTP-HUS; the most important diagnostic criterion, but also the most difficult, is the exclusion of alternative etiologies.^{1,2} ADAMTS13 (A Disintegrin And Metalloprotease with ThromboSpondin-1-like domains), an enzyme required for normal proteolytic processing of von Willebrand factor (VWF), is important in the pathophysiology of TTP,³ but patients may

have characteristic presenting features and clinical courses without severe ADAMTS13 deficiency.⁴

The critical element of initial management of patients with suspected TTP-HUS is the decision regarding plasma exchange treatment. For patients with TTP and adult patients with HUS, plasma exchange treatment is essential.^{5,6} We therefore describe these syndromes collectively by the term TTP-HUS. Because plasma exchange carries the risk of critical complications and even death,^{7,8} the indication for its use must be firm. However, the diagnosis of TTP-HUS is often not firm. Many disorders can mimic TTP-HUS, including systemic infections caused by bacteria, fungi, rickettsiae, or viruses; autoimmune disorders, such as systemic lupus erythematosus and scleroderma; complications of pregnancy, such as severe preeclampsia and HELLP (hemolysis, elevated liver function tests, and low platelets) syndrome; malignant hypertension; and systemic malignant disorders.²

Manuscript received March 16, 2005; accepted May 4, 2005.

Correspondence to: James N. George, MD, Hematology–Oncology Section, The University of Oklahoma Health Sciences Center, PO Box 26901, Oklahoma City, OK 73190; telephone: 405-271-4222; fax: 405-271-6444; e-mail: jim-george@ouhsc.edu.

Commun Oncol 2005;2:339–343 © 2005 Elsevier Inc. All rights reserved.

In The Oklahoma TTP-HUS Registry, 1989–2005, 12 of 329 patients who had been initially diagnosed with TTP-HUS and treated with plasma exchange were subsequently found to have a disseminated malignant disorder that was the cause of their acute illness. A patient who illustrates this diagnostic dilemma is presented; her laboratory findings and clinical course are summarized in Table 1.

Case report

A 52-year-old white woman presented to the hospital emergency room on September 18, 2000, with an acute onset of right upper abdominal pain and syncope. Despite developing progressive dyspnea and weakness over the past 2 weeks, she had continued to work as a teacher, including on the day of admission.

Three years before admission, the patient had had a mastectomy for breast cancer; 4 of 17 axillary lymph nodes were involved with metastatic carcinoma. She received adjuvant

treatment with six cycles of cyclophosphamide, doxorubicin, and 5-fluorouracil. Findings from her most recent examination, conducted 18 months prior to this hospitalization, were normal, including blood counts and chemistry profile.

Physical examination and laboratory findings

Physical examination on admission was unremarkable except for abdominal tenderness; she was alert, and there were no neurologic abnormalities. Laboratory evaluation demonstrated severe anemia (hematocrit, 25%) and thrombocytopenia (platelet count, 17,000/ μ L). Hemolysis was the apparent cause of the anemia, as the bilirubin level was 5.5 mg/dL, with only 1.6 mg/dL direct-reacting. A direct Coombs' test was negative. The serum creatinine level (0.7 mg/dL) and coagulation tests (international normalized ratio [INR], 1.2; activated partial prothrombin time, 25 seconds; fibrinogen concentration, 424 mg/dL) were normal.

The initial impression was acute cholecystitis, and surgery was considered.

Clinical course

Ultrasound examination of the gallbladder and a chest x-ray were normal; computed tomographic (CT) scans of the abdomen and pelvis were also normal. On the second hospital day, September 19, she was seen by her primary hematology/oncology physician, who advised that surgery be canceled and that TTP-HUS be considered because of the thrombocytopenia and microangiopathic hemolytic anemia. Her LDH level on that day was 1,431 U/L (normal level, < 200 U/L), and RBC fragments were noted on a peripheral blood smear.

Plasma exchange was begun on September 20. She became confused later that day, but the confusion improved after a second plasma exchange treatment the following day. However, on September 21, she developed respiratory distress and required administration of oxygen by face mask. Pulmonary embolism was confirmed by a spiral chest CT scan, which demonstrated multiple small emboli in the left upper lobe and both lower lobes. An echocardiogram demonstrated a dilated, akinetic right ventricle, consistent with the diagnosis of multiple pulmonary emboli. Because of her severe thrombocytopenia and also because an ultrasound study of her leg veins was normal, heparin was not given. Despite improvement of her mental status, the thrombocytopenia and anemia remained severe. On the sixth hospital day, she suffered respiratory arrest and died. Throughout her hospital course, no infection was identified; all blood and urine cultures were negative.

Diagnosis

Initial autopsy results revealed no apparent cause of death. There was no macroscopic tumor, and, remarkably, no pulmonary emboli were identified. However, subsequent micro-

TABLE 1
Summary of patient's laboratory data and clinical course

Date	Hct (%)	Platelets*	Other laboratory data, clinical course
7-23-97	–	–	Mastectomy for breast carcinoma (2.0 × 2.0 × 1.5 cm); 4/17 axillary nodes positive
8-15-97 to 12-5-97	–	–	Chemotherapy: 6 cycles of cyclophosphamide, doxorubicin, and 5-fluorouracil (CAF)
4-19-99	44	215	Routine follow-up; total bilirubin, 0.6 mg/dL
9-18-00	25	17	Admitted to hospital with acute abdominal pain; RBC transfusion
9-19-00	40	18	CT of abdomen and pelvis normal; LDH level, 1,431 U/L; creatinine level, 0.7 mg/dL; total bilirubin level, 5.5 mg/dL (direct, 1.6 mg/dL); INR, 1.2; APTT, 25 s; fibrinogen concentration, 424 mg/dL; direct Coombs' test, negative; RBC fragments noted; TTP-HUS suspected
9-20-00	33	12	Initial plasma exchange; platelet transfusion; spiral chest CT reveals multiple pulmonary emboli
9-21-00	28	24	Second plasma exchange; hypoxia; confusion
9-22-00	27	21	Third plasma exchange; RBC transfusion; clinical improvement
9-23-00	34	28	Respiratory arrest; death

APTT = activated partial prothrombin time; CT = computed tomography; Hct = hematocrit; INT = international normalized ratio; LDH = lactate dehydrogenase; RBC = red blood cell; TTP-HUS = thrombotic thrombocytopenic purpura-hemolytic uremic syndrome

* Platelet count × 10³/ μ L

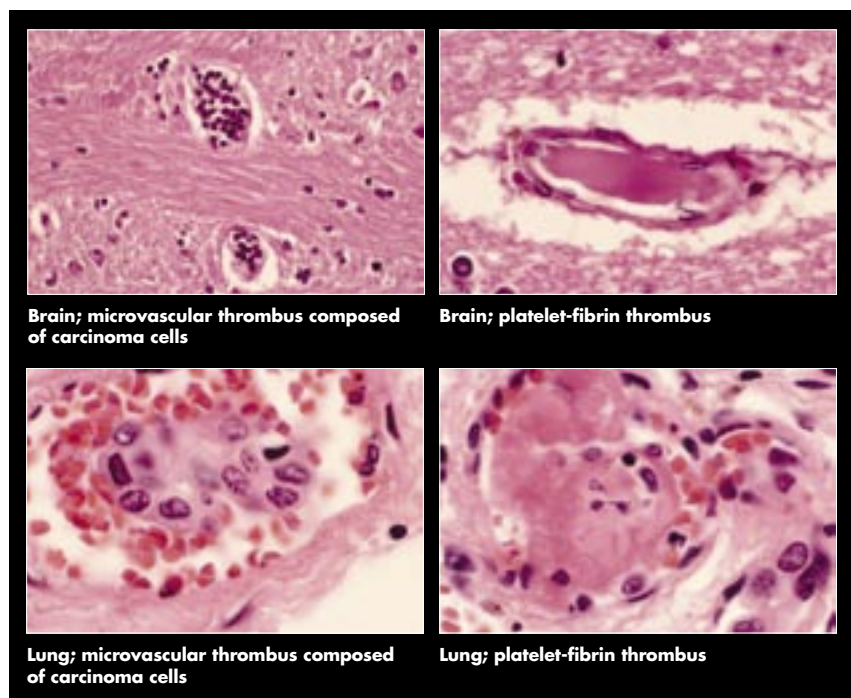


FIGURE 1 Microscopic tissue sections from the autopsy of the patient presented in the case report. Autopsy data and photomicrographs courtesy of Stephen C. Ingels, MD.

scopic examination revealed small intravascular clusters of metastatic adenocarcinoma cells, consistent with breast ductal carcinoma, in numerous organs, including the brain, heart, lungs, esophagus, liver, spleen, kidneys, adrenal glands, lymph nodes, and bone marrow (Figure 1). Platelet-fibrin thrombi, the characteristic hyaline thrombi of TTP-HUS, were also present in her capillaries and arterioles. Although no macroscopic pulmonary emboli were present, tumor cell emboli and platelet-fibrin thrombi (Figure 1) were detected in many small pulmonary vessels.

Comment

Even though this woman had a history of breast cancer, her presentation was sufficiently suggestive of TTP-HUS to deceive her physicians. Microangiopathic hemolytic anemia and thrombocytopenia were severe. In the absence of an alternative explanation, and with the lack of evidence for disseminated intravascular coagulation (DIC), TTP-HUS was

an appropriate diagnosis and plasma exchange was appropriate treatment. Although the acute respiratory distress seemed inconsistent with this diagnosis, pulmonary thrombi may occur in TTP-HUS. In retrospect, a bone marrow biopsy might have revealed the correct diagnosis of metastatic carcinoma.

Discussion

Occult systemic malignant disorders can mimic all of the clinical features of TTP-HUS. The first description of microangiopathic hemolytic anemia in 1962 was reported in 25 patients; 6 were diagnosed with TTP, and 5 patients were diagnosed with systemic malignant disorders, including gastric carcinoma in 3, lung carcinoma in 1, and prostate carcinoma in 1.⁹ The term “microangiopathic” implies that hemolysis is caused by partial occlusion of the arterioles, with the turbulence and high shear stress resulting in RBC fragmentation. Thrombocytopenia may also be caused by platelet consumption at

the sites of circulatory turbulence and vascular occlusion. The thrombotic microangiopathy in TTP-HUS may have a variety of etiologies, including a deficiency of ADAMTS13, which allows platelet clumping to occur on the endothelial cell surface³; Shiga toxin from enterohemorrhagic strains of *Escherichia coli*, which causes endothelial damage³; and drug-dependent antibodies that target platelets and endothelial cells.¹⁰ The clinical manifestations of systemic malignancy may be the same as TTP-HUS if disseminated microscopic metastases occur that cause vascular occlusion.

Microangiopathic hemolytic anemia is an uncommon but well-recognized manifestation of metastatic malignancies.¹¹ In most patients, the metastatic malignancy is clinically apparent, but in as many as one third of patients, the diagnosis of metastatic cancer is made after patients present with microangiopathic hemolytic anemia.^{12–16} Occasionally, the microangiopathic hemolytic anemia is the initial presentation in a patient not previously known to have cancer.^{13,14,16–18} When thrombocytopenia is also present and there is no evidence of DIC, TTP-HUS may appear to be the most likely diagnosis.¹⁹ The diagnosis of TTP-HUS may seem even more likely when the onset of microangiopathic hemolytic anemia and thrombocytopenia is abrupt and the clinical course is rapid, rather than gradual and progressive.^{13,15,16,20}

In some patients, as in the one described here, metastatic tumor is not apparent at autopsy until microscopic tissue sections are examined.^{12,21} The microscopic examination primarily reveals occlusion of arterioles and capillaries by clumps of cancer cells, but vascular occlusion by platelet-fibrin thrombi may also occur.^{11,14–16} The platelet-fibrin thrombi may be caused by stasis, proximal to the tumor emboli, or may result from damage to the vascular endothelium by the tumor cells.¹⁵

TABLE 2

Malignant disorders discovered in 12 patients initially diagnosed with TTP-HUS and treated with plasma exchange

Disorder	n
Non-small cell lung carcinoma	3
Breast carcinoma	2
Non-Hodgkin's lymphoma	2
Pancreatic carcinoma	1
Renal cell carcinoma	1
Acute lymphoblastic leukemia	1
Myelodysplasia	1
Kaposi's sarcoma*	1

TTP-HUS = thrombotic thrombocytopenic purpura-hemolytic uremic syndrome

* Patient also had HIV infection.

Our experience documents the variety of malignant disorders that can mimic TTP-HUS (Table 2). In each of these 12 patients, as illustrated by the patient described in this report, diagnostic clinical features of TTP-HUS were present and plasma exchange treatment was appropriate. In all of these patients, the diagnosis of disseminated malignancy was not ini-

tially apparent but was subsequently made by biopsy or autopsy. However, as this case report clearly demonstrates, in the absence of autopsy examination, other patients considered to have idiopathic TTP-HUS may also have had undetected underlying disseminated malignancy.

Look for clinical clues

Earlier recognition of cancer and initiation of treatment could improve survival. Our experience suggests several clinical clues that may alert the physician to the possibility that disseminated malignancy is the etiology of microangiopathic hemolytic anemia and thrombocytopenia (Table 3).

■ A history of cancer, as in the patient reported here, should trigger a careful consideration of recurrent cancer. Even when the initial evaluation, including imaging studies, does not reveal any evidence of cancer, disseminated microvascular metastatic disease remains a possibility. A short duration of symptoms does not exclude metastatic carcinoma.²⁰

■ Pulmonary involvement is uncommon

in TTP-HUS²²; therefore, the diagnosis of TTP-HUS is uncertain in patients with pulmonary infiltrates.

■ Patients with presumed TTP-HUS who have respiratory failure should be investigated thoroughly for an alternative etiology. Respiratory failure with evidence of multiple pulmonary emboli may be the presenting feature of patients with disseminated microvascular metastatic cancer.²⁰

■ Many patients with disseminated metastatic malignancy have evidence of DIC, although coagulation tests may be normal, as in this case report and others.^{11,17,20} Conversely, the presence of DIC is often said to exclude the diagnosis of TTP-HUS. However, some patients with classic TTP-HUS and extensive tissue ischemia may have DIC.

■ Patients with severe hemolysis and many circulating polychromatophilic reticulocytes may also have circulating nucleated RBCs. However, the presence of many nucleated RBCs together with immature myeloid cells in the peripheral blood suggests an abnormality of marrow architecture, such as that caused by bone marrow metastases. This hematologic picture, described as a leukoerythroblastic reaction, may also cause RBC abnormalities, including the appearance of schistocytes, the defining feature of microangiopathic hemolytic anemia.

■ An elevated serum LDH level is characteristic of TTP-HUS, resulting from intravascular hemolysis and also from tissue ischemia caused by the thrombotic microangiopathy.²³ However, extreme elevations of serum LDH levels more likely may indicate spontaneous tumor lysis associated with aggressive malignancies.

■ Finally, patients with TTP-HUS typically respond to plasma exchange. The response may not be immediate and may not be sustained, but the absence of a response is uncommon. Therefore, the absence of a response to plasma exchange is an additional criterion for concern about the accuracy of

TABLE 3

Clinical features that may suggest disseminated malignancy as an alternative diagnosis in patients with assumed TTP-HUS

Clinical feature	Comment
History of cancer	Even when the clinical evaluation and results of imaging studies are normal, metastatic cancer must be suspected.
Pulmonary infiltrates	Rare in TTP-HUS
Respiratory failure	Acute respiratory symptoms are rare in TTP-HUS. Pulmonary microscopic vascular tumor emboli can cause thrombotic microangiopathy.
Disseminated intravascular coagulation (DIC)	Although DIC is commonly associated with metastatic carcinoma, coagulation tests may be normal.
Nucleated red blood cells and immature myeloid cells on peripheral blood smear	These abnormalities may accompany the marrow response to severe hemolysis, but they more commonly indicate marrow infiltration by tumor.
Extreme elevation of lactate dehydrogenase (LDH) level	Although an elevated LDH level, caused by hemolysis and tissue ischemia, is characteristic of TTP-HUS, levels exceeding 5,000 U/L are more commonly caused by tumor lysis.
No response to plasma exchange treatment	Patients with TTP-HUS typically respond promptly to plasma exchange. No response should cause concern about the diagnosis.

TTP-HUS = thrombotic thrombocytopenic purpura-hemolytic uremic syndrome

an initial diagnosis of TTP-HUS.

For patients with any of the causes for diagnostic concern outlined in Table 3, a bone marrow biopsy and other additional diagnostic procedures may be appropriate.

Lessons learned

The patient presented in this report emphasizes the importance of many of these clinical issues. During her hospitalization, recurrent breast cancer was always a consideration but was never apparent. The presenting symptom of acute abdominal pain was consistent with a diagnosis of TTP-HUS, as abdominal pain is a common presenting symptom of classic TTP-HUS.⁴ In retrospect, this symptom was probably due to the diffuse hepatic microvascular metastases. Although multiple pulmonary emboli are a rare feature of TTP-HUS, the appearance of pulmonary emboli with no evidence of venous thrombosis in the legs was thought to be consistent with disseminated thrombotic manifestations of TTP-HUS. This patient's sudden death was assumed to be caused by pulmonary emboli. When the initial autopsy observation revealed no pulmonary emboli and no alternative explanation for her clinical features, including no apparent recurrent breast cancer, this patient was assumed to have idiopathic TTP-HUS,⁴ even though her clinical features were unusual. A bone marrow biopsy might have revealed the metastatic carcinoma; however, this procedure is not commonly considered part of the evaluation of a patient with suspected TTP-HUS.

The microscopic observation of disseminated microvascular metastatic carcinoma, consistent with breast carcinoma, clearly explained all of the clinical features of this patient's terminal illness. The observation of arteriole and capillary thrombi composed of clusters of metastatic cancer cells and also the presence of thrombi composed of platelets and fibrin—the characteristic hyaline thrombi of

TTP-HUS—explain why this patient's clinical features were essentially indistinguishable from idiopathic TTP-HUS.

In conclusion, physicians must remain vigilant for alternative etiologies for acute and severe thrombocytopenia and microangiopathic hemolytic anemia, even when TTP-HUS appears to be a secure diagnosis and plasma exchange treatment has been started. Occult systemic malignancies can mimic all clinical features of TTP-HUS.

Acknowledgment: We thank Sherri S. Durica, MD, for her advice and support.

References

- George JN. How I treat patients with thrombotic thrombocytopenic purpura-hemolytic uremic syndrome. *Blood* 2000;96:1223-1229.
- George JN, Vesely SK, Terrell DR. The Oklahoma thrombotic thrombocytopenic purpura-hemolytic uremic syndrome (TTP-HUS) registry: a community perspective of patients with clinically diagnosed TTP-HUS. *Semin Hematol* 2004;41:60-67.
- Moake JL. Thrombotic microangiopathies. *N Engl J Med* 2002;347:589-600.
- Vesely SK, George JN, Lammle B, et al. ADAMTS13 activity in thrombotic thrombocytopenic purpura-hemolytic uremic syndrome: relation to presenting features and clinical outcomes in a prospective cohort of 142 patients. *Blood* 2003;101:60-68.
- Rock GA, Shumak KH, Buskard NA, et al. Comparison of plasma exchange with plasma infusion in the treatment of thrombotic thrombocytopenic purpura. *N Engl J Med* 1991;325:393-397.
- Rock G, Shumak K, Kelton J, et al. Thrombotic thrombocytopenic purpura: outcome in 24 patients with renal impairment treated with plasma exchange. *Transfusion* 1992;32:710-714.
- Rizvi MA, Vesely SK, George JN, et al. Complications of plasma exchange in 71 consecutive patients treated for clinically suspected thrombotic thrombocytopenic purpura-hemolytic uremic syndrome. *Transfusion* 2000;40:896-901.
- McMinn JR, Thomas IA, Terrell DR, et al. Complications of plasma exchange in patients treated for clinically suspected thrombotic thrombocytopenic purpura-hemolytic uremic syndrome: an additional study of 78 consecutive patients. *Transfusion* 2003;43:415-416.
- Brain MC, Dacie JV, Hourihane OB. Microangiopathic hemolytic anemia: the possible role of vascular lesions in pathogenesis. *Br J Haematol* 1962;8:358-374.
- Kojouri K, Vesely SK, George JN. Quinine-associated thrombotic thrombocytopenic purpura-hemolytic uremic syndrome: frequency, clinical features, and long-term outcomes. *Ann Intern Med* 2001;135:1047-1051.
- Antman KH, Skarin AT, Mayer RJ, Hargreaves HK, Canellos GP. Microangiopathic hemolytic anemia and cancer: a review. *Medicine* 1979;58:377-384.
- Stratford EC, Tanaka KR. Microangiopathic hemolytic anemia in metastatic carcinoma. *Arch Intern Med* 1965;116:346-350.
- Wintebauer RH, Elfenbein IB, Ball WC Jr. Incidence and clinical significance of tumor embolization to the lungs. *Am J Med* 1968;45:271-290.
- Lohrmann HP, Adam W, Heymer B, Kubanek B. Microangiopathic hemolytic anemia in metastatic carcinoma. *Ann Intern Med* 1973;79:368-375.
- Murgo AJ. Thrombotic microangiopathy in the cancer patient including those induced by chemotherapeutic agents. *Semin Hematol* 1987;24:161-177.
- Schriner RW, Ryu JH, Edwards WD. Microscopic pulmonary tumor embolism causing subacute cor pulmonale: a difficult antemortem diagnosis. *Mayo Clin Proc* 1991;66:143-148.
- Lin Y-C, Chang H-K, Sun C-F, Shih L-Y. Microangiopathic hemolytic anemia as an initial presentation of metastatic cancer of unknown primary origin. *South Med J* 1995;88:683-687.
- Polukhin E, Balla A, Chary K, Mezhir J. Microangiopathic hemolytic anemia as the first manifestation of lung adenocarcinoma. *South Med J* 2001;94:550-551.
- Kressel BR, Ryan KP, Duong AT, Berenberg J, Schein PS. Microangiopathic hemolytic anemia, thrombocytopenia, and renal failure in patients treated for adenocarcinoma. *Cancer* 1981;48:1738-1745.
- Systrom DM, Mark EJ. Case records: a 55-year-old woman with acute respiratory failure and radiographically clear lungs. *N Engl J Med* 1995;332:1700-1708.
- Yao DX, Fliedner DB, Hoda SA. Pulmonary tumor thrombotic microangiopathy—an often missed antemortem diagnosis. *Arch Pathol Lab Med* 2001;125:304-305.
- Ridolfi RL, Bell WR. Thrombotic thrombocytopenic purpura: report of 25 cases and review of the literature. *Medicine* 1981;60:413-428.
- Cohen JD, Brecher ME, Bandarenko N. Cellular source of serum lactate dehydrogenase elevation in patients with thrombotic thrombocytopenia purpura. *J Clin Apheresis* 1998;13:16-19.

ABOUT THE AUTHORS

Affiliations: Kristin K. Francis, MD, is a resident in internal medicine, Kiarash Kojouri, MD, MPH, is a fellow in hematology-oncology, and James N. George, MD, is Professor of Medicine, The University of Oklahoma Health Sciences Center, Oklahoma City, OK.

Financial conflicts: None reported.